

IP. No: 3119



SRI MUTHUKUMARAN MEDICAL COLLEGE HOSPITAL AND RESEARCH INSTITUTE

Chikkarayapuram, Near Mangadu, Chennai - 600069

Phone No: 044- 66344000 / 65650839

Email: info@smmchri.res.in | Web: www.smmchri.res.in

IN PATIENT RECORD

Patient Name: Mrs. Gowthami Age: 27 Sex: F

UHID. No: 2370476 IP. No: 3119

Department: Gs Unit: J Ward: FSH Bed:

Date of Admission: 11/3/24 Date of Surgery: 13/3/24 Date of Discharge:

PROCESS CHECK

Assembling

Deficiency check

Diagnostic index Resolved

Operation index Sx: Excision of biopsy done on 13/3/24. mesh repair

Surgeon index

Checked by

Filling check

Date of filling

DEAN
SRI MUTHUKUMARAN MEDICAL COLLEGE
HOSPITAL & RESEARCH INSTITUTE
Chikkarayapuram Near Mangadu
Chennai-600069

CONFIDENTIAL RECORD

RETURN TO MRD, PLEASE



Sri Muthukumar Medical College Hospital and Research Institute
Chikkarayapuram, Near Mangadu, Chennai - 600069

ADMISSION ORDER

MRD Use	UHID No 2370476	IP No 2024031119
Patient Name	Mr Gowthami	Age / Sex 27/F
Date of Admission	11-03-2024	Source of Admission <input checked="" type="checkbox"/> OPD <input type="checkbox"/> Casualty
Provisional Diagnosis	Right Desmoid Tumour	
Mode of Payment	Cash <input type="checkbox"/> Credit <input type="checkbox"/> Others <input type="checkbox"/>	
Type of Ward	Female Surgical ward	Department General Surgery
Admitting Doctor's Name (In Caps) & Designation	DR. SANDHYA K. M.S. SENIOR RESIDENT.	Admission Doctor's Signature
Casualty Transfer	Ward Female Surgical ward	Dept. Surgery Unit I
Admission Clerk's Name & Emp.No		Admission Clerk's Signature


DEAN
SRI MUTHUKUMARAN MEDICAL COLLEGE
HOSPITAL & RESEARCH INSTITUTE
Chikkarayapuram Near Mangadu
Chennai-600 069



Sri Muthukumar Medical College Hospital and Research Institute

Chikkarayapuram, Near Mangadu, Chennai - 600069

IN PATIENT ADMISSION RECORD

UHID. No	2370476	I.P. No	2024031119
Patient Name	Mrs Gowthami	Age	27/F
S/W/D. of	Dilli Ganesh	Sex	M <input type="checkbox"/> F <input checked="" type="checkbox"/> TG <input type="checkbox"/>
Contact Ph. No	6383935014	Marital Status	
Address	Muvugan 101st Pudhu neller	Occupation	
		Religion	
Date of Admission	8/11/24	Time of Admission	1:57 P.M
Department	Gr Sur	Unit	
Ward	F.Sur	Bed No	
Transferred	From	To	
MLC No		MLC Date	

Previous Admissions (Last 3 Admissions)							
IP. No.	Admission Date	Consultant	Discharge Date				
Date of Discharge		Time of Discharge					
<input type="checkbox"/>	<input type="checkbox"/>	<input type="checkbox"/>	<input type="checkbox"/>	<input type="checkbox"/>	<input type="checkbox"/>	<input type="checkbox"/>	<input type="checkbox"/>
Cured	Relieved	Controlled	AMA	Referral	Absconded	Expired	ICD Code
Final Diagnosis (in capital letters)							
Operation Procedure (in capital letters)							
Cause of Death (If pt. expired)							
MRT/MRC		Date of Surgery: _____ DEPARTMENT OF SURGERY SRI MUTHUKUMARAN MEDICAL COLLEGE AND RESEARCH INSTITUTE Chikkarayapuram, Near Mangadu, Chennai-600069. DR SANDHYA K.M.S Treating Physician				Unit Chief /H.O.D	

DEAN
SRI MUTHUKUMARAN MEDICAL COLLEGE
HOSPITAL & RESEARCH INSTITUTE
 Chikkarayapuram Near Mangadu
 Chennai-600069



Sri Muthukumaran Medical College Hospital and Research Institute
Chikkarayapuram, Near Mangadu, Chennai - 600069

INITIAL ASSESSMENT RECORD

Name	Ms Gowtham	Age	27yr	Gender	Female	Ward/Bed	FSW
UHID. No	2370476	IP. No		Date	11/04/21	Time	
Mode of admission	OPD / EMS / REF.	Ref Dr.					
Blood group	O+Ve	Allergy				Dept./Unit	S-I.

HISTORY & PHYSICAL EXAMINATION

Informant / Reliability: Self / good

Chief complaints with duration: c/o pain in Right Fliac fossa x 3 months.
Pricking type of pain, intermittent in nature.

History of present illness (Elaborate symptoms in detail): Apparently started 3 months ago after which patient developed right side pain in abdomen, pricking type of pain, Intermittent nature. No H/o Fever, Vomiting, burning micturition.

Past medical history (Including chronic illness): Chest pain / HT / DM / TB / Asthma

Hypothyroidism x 2 yrs back. [now Thyroid levels are Normal]
=> no other known co-morbidities

Surgical history (year / procedure / indication / hospital):

=> LSCS done 4 yrs back.

=> St. ent. ad. w.

Menstrual history: Menarche at 13 yrs. Regular. 4/28 days.

Obstetric history: not associated with pain & c/o
P4 L3 A1.

Personal history: No oral bowel & bladder habit.

Family history: Consumes Mixed diet.

Family history:

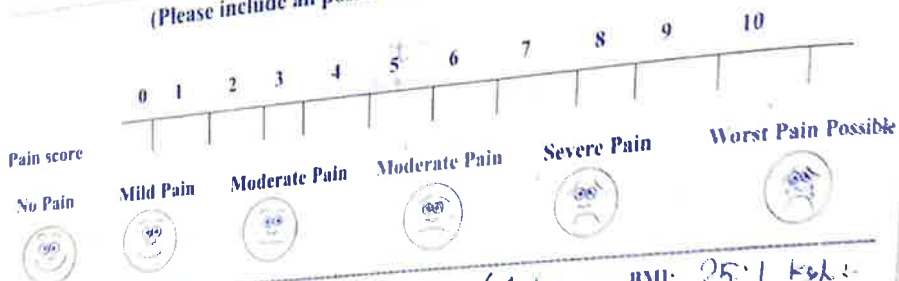
Socio economic history:

DEAN
SRI MUTHUKUMARAN MEDICAL COLLEGE
HOSPITAL & RESEARCH INSTITUTE
Chikkarayapuram, Near Mangadu
Chennai-600 069

Review of symptoms: (Please tick none if no symptoms are present)

- ENT None Ear ache Ear Discharge Tinnitus Vertigo Voice Change Snoring
- EYE None Eye redness Eye Discharge Eye Pain Vision Disturbance
- CVS None Cough Sputum Hemoptysis Shortness Of breath Chest pain
- Respiratory Palpitation Edema Syncope Any other
- Gastrointestinal None Abdominal pain Diarrhea Constipation Vomiting
- Hematemesis Bleeding Swelling Worms Jaundice Any Other
- Genito-urinary None Hematuria Dysuria Nocturia Oliguria H/O stones Retention
- Dialysis Infertility Impotence Penile/Vaginal Any other
- Hematologic None Weakness Bleeding Blood Hemolytic disease
- Lymphatic Edema Any other H/O DVT
- Skin Integument None Rash Itching Discoloration Ulceratio
- Breast swelling Nipple discharge Any other
- Breast
- Musculoskeleta None Weakness Numbness Pain Headache Diplopla
- Neurological Syncope Vertigo Stroke Claudication Rest pain in legs
- Psychiatric None Anxious Agitated Depressed Any other
- Endocrine/Immunologic None Thyroid disease Diabetes Any other

(Please include all positive & relevant findings)



Pain core site: _____ Height: 167 cm Weight: 66 kg BMI: 25.1 kg/m²

General examination: Gc for Af. hals

Temp: _____
 PR: _____
 BP: _____
 RR: _____
 SpO₂: _____
 CBC: _____

Pallor: _____
 Icterus: _____
 Cyanosis: _____
 Clubbing: _____
 Lymphadenopathy: _____
 Thyromegaly: _____
 Oedema: _____

DEAN
 SRI MUTHUKUMARAN MEDICAL COLLEGE
 HOSPITAL & RESEARCH INSTITUTE
 Chikkarayapuram Near Mangadu
 Chennai-600 069



Sri Muthukumaran Medical College Hospital and Research Institute
Chikkarayapuram, Near Mangadu, Chennai - 600069

SYSTEMIC EXAMINATION

CVS: S₁S₂ ⊕

RS: B/L NVBJ ⊕.

CNS: NFN D.

P/A: Soft, SPT Scar ⊕
Bowel sounds ⊕

Detailed examination of system affected (additional):

LE: Spt. Tenderness ⊕ in the RIF. A swelling of size 6 x 3 cm present in the RIF, smooth surface, firm in consistency, irregular shape, mobility ⊕ in both horizontal & vertical planes. Skin above the swelling pinchable, swelling is non-fluctuant, non-pulsatile, non-transilluminant. On Raising the head swelling show reduced mobility. It is not fixed to underlying bone. previous Inusual biopsy scar present in RIF; healthy.

Investigation done prior to admission:

S.NO	INVESTIGATIONS	REPORT

DEAN
SRI MUTHUKUMARAN MEDICAL COLLEGE
HOSPITAL & RESEARCH INSTITUTE
Chikkarayapuram, Near Mangadu
Chennai-600 069

PROVISIONAL DIAGNOSIS
Right Desmoid Tumour
(Internal oblique, transverse abdominis)

DEPARTMENT OF SURGERY

Completed by	Dr. Dharani	signature
Consultant	Dr. Sandhya S.K	signature
Date: 11/3/24	Time:	

PLAN OF TREATMENT

Investigations:

Treatment:

- Normal diet.
- T. AMOXICLAV 625mg P/O 1-0-1
- T. METRONIDAZOLE 400mg P/O 1-1-1
- T. PAN 40mg P/O 1-0-1 (B/F).

Diet:

Handwritten signature and date: 25/10/14
Faint stamp: SRI MUTHUKUMARAN MEDICAL COLLEGE HOSPITAL & RESEARCH INSTITUTE

DEAN
SRI MUTHUKUMARAN MEDICAL COLLEGE
HOSPITAL & RESEARCH INSTITUTE
Chikkarayapuram Near Mangadu
Chennai-600 069



Sri Muthukumar Medical College Hospital and Research Institute
Chikkarayapuram, Near Mangadu, Chennai - 600069

IN-PATIENT PROGRESS RECORD

Name	Mrs. Gowthami	Age	31	Sex	M <input type="checkbox"/> F <input checked="" type="checkbox"/> TG <input type="checkbox"/>	UHID No	2370076
Dept	CS	Unit	T	Ward	ESH	Bed	IP No 03119

Date & Time	Clinical Notes & Treatment	Investigations
-------------	----------------------------	----------------

12/03/24
7:45 AM

c/s/B AP/PL/CRMI-SI

PR - 76 bpm
BP - 110/70 mmHg
SpO₂ - 99% @ RA
RR - 16/min

Δ (R) Desmoid Tumor
Planned for wide local excision c fascia
lata craft / Repair on 13/03/24 JGA.

pt c/o pain in the RIF on & off.
No c/o dental Tooth ache.

Inv - 4/3/24
Hb - 12.4 gm/l
Tc - 8,800

o/e: ac Fair, Afebrile, Adequately hydrated.

Ade:
- Normal Diet

N/L/S/H 59/34/02/05 S/E: CVS: S, S₂ D
BT - 2 mins RS: B/LAEC
CT - 5 mins ENS: HMF D

Na⁺ - 136 mmol/l
K⁺ - 4.0 mmol/l
Cl⁻ - 104 mmol/l

P/A: soft, Tenderness ⊕ in the RIF, A
Swelling of size 6x3cm ⊕ in RIF which is smooth
surface, firm in consistency, irregular in shape c mobility
⊕ in both horizontal & vertical planes, swelling is
non-fluctuant, non-pulsatile, non-transilluminant
skin above the swelling is pichable, on head raising
swelling shows reduced mobility, & not fixed to
underlying bony structures. Previous sx (cisional
biopsy) Scar present in RIF.

⊕₂ } - T Amoxiclav 625mg 1-0-1
- T METRONIDAZOLE 400mg 1-1-1
- T PAN 40mg B/F 1-0-1

- To do:
- Repeat Hb, BT, CT, Sr Electrolytes Tonight
 - Reserve adequate Blood Products
 - follow ~~Post~~ Pre-op orders from 6 pm.

DEAN
SRI MUTHUKUMAR MEDICAL COLLEGE
HOSPITAL & RESEARCH INSTITUTE
Chikkarayapuram Near Mangadu
Chennai - 600069

[Signature]
13/11/24



Sri Muthukumar Medical College Hospital and Research Institute
Chikkarayapuram, Near Mangadu, Chennai - 600069

IN-PATIENT PROGRESS RECORD

Name	MSI Gowthaman	Age	27	Sex	M <input type="checkbox"/> F <input checked="" type="checkbox"/> TG <input type="checkbox"/>	UHID.No	2370426
Dept	US	Unit	I	Ward	1513	IP.No	03119
Date & Time		Investigations					

12/3/24 **PRE-OP ORDERS**

- To do Hb, BT, CT, Sr. Electrolytes Today night X & collect reports Tomorrow morning
- CLEAR LIQUIDS From 8pm
- NPO From 10pm
- PROCTOLYSIS ENEMA @ 10 pm
- INFORMED CONSENT
- HIGH RISK CONSENT
- ICU CONSENT
- PAIN PREPARATION
 - FROM BELOW NIPPLE TO MID THIGH
 - FROM INFRA SCAPULAR TO GLUTEAL CLEFT
- T PAN 40mg p/o - STAT
- T ANXIT 0.5mg p/o - STAT
- check Availability of VYPRO MESIL from Patient & inform.

13/3/24 **ON DAY OF SURGERY**

- inj XONE 1gm IV - STAT (NID)
- inj PAN 40mg IV - STAT
- inj EMSESEF 4mg IV - STAT
- Shift PATIENT TO OT BEFORE 8:30AM

DEPARTMENT OF SURGERY
SRI MUTHUKUMAR MEDICAL COLLEGE
CHIKKARAYAPURAM
CHENNAI - 600069
13/3/24

DEAN
SRI MUTHUKUMAR MEDICAL COLLEGE
HOSPITAL & RESEARCH INSTITUTE
Chikkarayapuram Near Mangadu
Chennai-600 069



Sri Muthukumaran Medical College Hospital and Research Institute
Chikkarayapuram, Near Mangadu, Chennai - 600069

NURSES DAILY RECORD

Name	Mrs. <u>C. Aravindhan</u>		Age	<u>27</u>	Sex	M <input type="checkbox"/> F <input checked="" type="checkbox"/> TG <input type="checkbox"/>	UHID No	<u>270476</u>	
Dept	<u>CS</u>	Unit	<u>2</u>	Ward	<u>ESH</u>	Bed	<u>-</u>	IP No	<u>3119</u>
Date & Hour	Nursing Notes							Signature with Name	
<u>12/3/20</u>	<p>C/S/B - DAA - Dr. Saranya. PG's - Dr. Deepak / Dr. Stephen</p> <p>Δ - (R) Desmoid tumor of (R) intercostal oblique / transverse abdominus</p> <p>Planned for - wide local excision</p> <p>O/E - conscious oriented afebrile</p>								
<u>04/03/20</u>	<p>B/E - CVS - S/S 2+ RL - B/L AE + P/A - soft CNS - NND</p>								
Hb - 12.4								Adr	
PCV - 35								- NPO for 8 hrs before sx	
BT - 2 mins								- Informed consent	
CT - 5 mins								- T. pzo lo / 2/0 night before	
Na - 136								- + Anxit 0.5mg / sz	
K ⁺ - 4.0								- T. pzo lo / IV morning of sx	
Cl - 104								- 2x Emeret 1mg	
								- prepare ports from infraglenoid region to gluteal cleft	
								- Reserve adequate blood products	
								- Monitor vitals / Inform sos	

[Handwritten Signature]

DEAN
 SRI MUTHUKUMARAN MEDICAL COLLEGE
 HOSPITAL & RESEARCH INSTITUTE
 Chikkarayapuram, Near Mangadu
 Chennai-600 069.



Sri Muthukumar Medical College Hospital and Research Institute
Chikkarayapuram, Near Mangadu, Chennai - 600069

NURSES DAILY RECORD

Name	Mrs. Gowthami		Age	07	Sex	M <input type="checkbox"/> F <input checked="" type="checkbox"/> TG <input type="checkbox"/>	UHID.No	22
Dept	CS	Unit	1	Ward	P313	Bed	-	IP.No
Date & Hour	Nursing Notes							Sign

13/3/24
4:30pm
Pt received in post-op ward
C/S/B AP/pa/CRMI-S1

POD-0
Δ: Desmoid Tumor of (R) Internal oblique & Transverse Abdominis
Sp: Excision of desmoid tumor (R) + Mesh Repair L.G.N. Epiduro
on 13/03/24
PR-51bpm
BP-110/60 mmHg

Spo₂ 97% O/F PE c/o Back pain, No c/o surgical site pain.
RR-16/min No h/o vomiting, fever, lightheadedness.

O/F GC Fair, conscious, oriented, Adequately hydrated
S/F CVS: S, S, A - NPO TILL FURTHER ORDER
RS: B/L ACO DNS 20
CNS: NMF0 - IVF RL 10 @ 100ml/h
NS 2B

Urine - Normal P/A: soft Tenderness in surgical site
No Bowel sounds.
D₁ - inj XONE 1gm IV 1-0-1
D_{1/3} - inj METRO 500mg IV 1-0-1

I₁ - Epidural catheter in situ - inj PAN 40mg IV 1-0-1
D₁ - CBD in situ - inj PARA 1gm IV 1-0-1

To do
- Repeat Hb, Tc, Dc, Platelets
- inj EMERGE 4mg IV S-O-S
- inj TRAMADOL 200 in 100ml NS IV S-O-S
- T/R/R/B/SPO C_{1/2} nd h₂ly
- I/O charting

Repeat Hb, Tc, Dc, Platelets Tomorrow morning & collect reports before 5AM

DEPARTMENT
Sri Muthukumar Medical College
Chikkarayapuram, Chennai

& A/P
(13/3/24)
137111

DEAN
SRI MUTHUKUMARAN MEDICAL COLLEGE
HOSPITAL & RESEARCH INSTITUTE
Chikkarayapuram Near Mangadu
Chennai-600 069



Sri Muthukumar Medical College Hospital and Research Institute
Chikkarayapuram, Near Mangadu, Chennai - 600069

NURSES DAILY RECORD

Name	Mrs. Gowthami		Age	27	Sex	M <input type="checkbox"/> F <input checked="" type="checkbox"/> TG <input type="checkbox"/>	UHID.No	2370476
Dept	C/S	Unit	2	Ward	FSH	Bed	r	IPNo 3119
Date & Hour	Nursing Notes							Signature with Name

13/03/24 C/S/B DAPA Dr. Chandresh /
Dr. Kamelwan / Dr. Amritha
DB: 02pm

Diag.: Desmoid Tumour of Right Internal
Oblique & transverse abdominis

BP - 110/70mmHg s/p: Excision of desmoid tumour (R)
PR - 60 bpm -> Need repair & GA & Epidural
SpO₂ - 100% @ RA

PT reviewed.
VAS - II

o/e: PT is conscious, oriented
Afebrile

<u>s/e</u> :	WS	NAD
	C/S	
	AS	
	P/A	

plan
Moulder intact
By from ...
Epidural top up PRN

DEAN
SRI MUTHUKUMARAN MEDICAL COLLEGE
HOSPITAL & RESEARCH INSTITUTE
Chikkarayapuram - Near Mangadu
Chennai - 600 069



Sri Muthukumar Medical College Hospital and Research Institute
Chikkarayapuram, Near Mangadu, Chennai - 600069

NURSES DAILY RECORD

Name	Mu. Yashwanthi	Age	47	Sex	M <input type="checkbox"/> F <input checked="" type="checkbox"/> PG <input type="checkbox"/>	UHID.No	237
Dept	CS	Unit	T	Ward	PCU	IPNo	3111
Date & Hour	Nursing Notes						
13/03/24	S/O DAA - Dr. Chandresh.						
7pm	PB's - Dr. Kamaladevi / Dr. Anmolika						
PR-64/min	patient reviewed						
BP-110/70mmHg	c/o surgical site pain						
	Epidural top up given i send of						
	0.025 / Bupivacaine.						
	post-top up intake						
	PR-62/min						
	BP-110/60mmHg						
	[Signature]						
	11609						
14/03/24	S/O DAA - Dr. Chandresh.						
7:15pm	PB's - Dr. Kamaladevi / Dr. Anmolika						
PR-68/min	patient reviewed						
BP-100/60mmHg	c/o surgical site pain						
	Epidural top up given i send of 0.125 / Bupivacaine						
	post-top up intake						
	PR-68/min						
	BP-100/60mmHg						
07:40pm	Epidural catheter removed						
	- Blue top scan & sham to staff nurse - RP						
	- No infiltration / abscess						
	- Pt not on any analgesic						
	[Signature]						
	11638						

DEAN
SRI MUTHUKUMARAN MEDICAL COLLEGE
HOSPITAL & RESEARCH INSTITUTE
Chikkarayapuram, Near Mangadu
Chennai-600 069



Sri Muthukumar Medical College Hospital and Research Institute
Chikkarayapuram, Near Mangadu, Chennai - 600069

NURSES DAILY RECORD

Name	Mu. Yowtharu		Age	27	Sex	M <input type="checkbox"/> F <input checked="" type="checkbox"/> TG <input type="checkbox"/>	UHID No	2220476
Dept	GS	Unit	I	Ward	RUW	Bed	IP No	2119
Date & Hour	Nursing Notes							Signature with Name
4/03/24 8:30am PODA	c/s B S-I AP SR PG CRMF							
	Δ - Desmoid Tumour of (R) Internal oblique and Transverse Abdominis							
	S/x: Excision of (R) Desmoid Tumour & Mesh Repair							
	↓ GA ↓ Epidural							
12-06 hr	pt c/o pain at surgical site On 13/03/24							
10-00/6000	O/E: Gr. fair. conscious							Adv -
	O/cb. Abdom. h/d/d							
	S/E: CV: S, J, I, D							IVF → IONS
	R/S: R/LAFO							→ IORL
	C/N: NENDD							→ IODNS
DT 65ml Blood Max with serum fluid 7-2200x 0-1850	P/A - Soft, BS (+)							- Sppt of clear fluids.
	(D ₂) - Inj. Xone 1g IV to-1							
	(D _{2/3}) - Inj. Metro 500mg IV							
assess	L/E - Abdomen Intact							
flatus.	No swelling.							
Paps 11-81	Drain in situ.							
To 9:00	- Inj. Para 1g IV							
PT 280	- Inj. Pam 40mg IV to-1							
	- Inj. Emaset 4mg IV SOS							
	- Inj. Tramadol 100mg PO 4hrly							
	S/B Dr. T. Srikumar (plastic)							
	Loop							
	pt c/o pain in back							
	A. Spontaneous Adv							
	To give warning dose of Inj. Para.							

SRI MUTHUKUMARAN MEDICAL COLLEGE
HOSPITAL & RESEARCH INSTITUTE
Chikkarayapuram Near Mangadu
Chennai-600 069

(Dr. Sandhya K M.S)

T.h
(Dr. Arumugam)



Sri Muthukumar Medical College Hospital and Research Institute
Chikkarayapuram, Near Mangadu, Chennai - 600069

NURSES DAILY RECORD

Name	Mu Gouthami	Age	27	Sex	M <input type="checkbox"/> F <input checked="" type="checkbox"/> TG <input type="checkbox"/>	UHID No	27704
Dept	GS	Unit	T	Ward	FLW	Bed	3119

Date & Hour: 14/3/2024 9.15pm

POD-11 c/s/B Duty PG (GSU-4)
 r/o Desmoid tumor of (R) IO & TA
 s/p- Excision of Desmoid tumor (R)
 + Mesh repair

r/o pain @ operated site (+) sed
 - cough (+)
 - numbness of (R) LL (+) Adv

Bp - 100/60 mmHg
 PR - 72 bpm
 Temp - 98.4 F
 SpO2 - 98% LRA
 O/E: Gc fair (IVF - on flow) IVF - as per order.
 pallor (on CBD/DT)
 hydration - fair tips of clear fluids
 Afebrile.

I/O
 DT - serosanguinous
 Passing flatus
 No leakage
 DT intact

(P) - to add
 Sy: Ascoril D plus 5ml stat
 (B) 2j. Xone 1g IV BD
 (B) 2j. Metro 500mg IV TDS.
 2j. Para 1g IV BD
 2j. Pan 40mg IV BD
 2j. Emeset 4mg IV SOS
 2j. Tramadol 100mg in 100ml NS IV SOS

[Handwritten signature]

Dr. B. SINDHUJA
 Resident
 MS General Surgery
 Reg No 116312

DEAN
 SRI MUTHUKUMARAN MEDICAL COLLEGE
 HOSPITAL & RESEARCH INSTITUTE
 Chikkarayapuram Near Mangadu
 Chennai-600 069



Sri Muthukumar Medical College Hospital and Research Institute
Chikkarayapuram, Near Mangadu, Chennai - 600069

NURSES DAILY RECORD

Name	Mu. Gowthami	Age	27	Sex	M <input type="checkbox"/> F <input checked="" type="checkbox"/> TG <input type="checkbox"/>	UHID No	23-20176
Dept	GS	Unit	I	Ward	FW	Bed	IP No 3119
Date & Hour	Nursing Notes						Signature with Name
7:30 AM 18/3/2024	<p>o/s/B Duty PG (GSU-4)</p> <p>c/o cough & expectoration No temp spikes Not passed stools passing flatus</p> <p>B/c - congested R/s - BAE No added sounds.</p>						<p>Adv</p> <p>to cont same order</p>
	<p>Bp - 100/70 PR - 80bpm Temp - (N) SpO₂ - 98% vRA</p>						
	<p>Dr. B. SINDHUJA Resident MS General Surgery Reg No 116312</p>						
	<p align="center"> DEAN SRI MUTHUKUMARAN MEDICAL COLLEGE HOSPITAL & RESEARCH INSTITUTE Chikkarayapuram Near Mangadu Chennai-600069 </p>						



Sri Muthukumar Medical College Hospital and Research Institute
Chikkarayapuram, Near Mangadu, Chennai - 600069

NURSES DAILY RECORD

Name	Mr. Gouthami		Age	27	Sex	M <input type="checkbox"/> F <input checked="" type="checkbox"/> TG <input type="checkbox"/>	UHID.No	3320476
Dept	GS	Unit	I	Ward	PSU	Bed	IP.No	31119
Date & Hour	Nursing Notes							Signature with Name
15/03/24 8:30 AM	C/S/B AP/PA/LRMI-ST							
POD 2	<p>Δ - Desmoid tumor of R INTERNAL OBLIQUE & TRANSVERSE ABDOMINAL S/P EXCISION OF R DESMOID TUMOR & MESH REPAIR L/OA L/Epidu on 13/03/24.</p>							
PR-Subpra	Pt c/o cough.							
BP-110/70 mmHg	Pt c/o numbness of R thigh.							
SpO2-99% @ RA	Pt able to tolerate oral feeds.							Adv:
RR-16/min	<p>O/E: ac. fair, conscious, oriented, Afebrile, Adequately hydrated.</p> <p>S/E: CVS: S, S, ⊕</p> <p>RS: B/L AEC ⊕</p> <p>CNS: NMF ⊕</p>							<p>- ORAL FLUIDS + SEMI SOLID FOOD</p> <p>- IVE $\left\{ \begin{array}{l} 10NS \\ 10RL \\ 10ANS \end{array} \right\}$ @ 120ml</p>
I-2500ml	P/A: soft. Tenderness ⊕ surgical site							D ₃ - 10j XONE 1gm IV 1-0
O-2530ml	Bowel sounds ⊕							D _{3/5} - 10j METRO 500mg IV 1-0
urine - normal colour	<p>W/E: Dressings intact, no seepage</p> <p>CBD in situ drain tube in situ</p> <p>: Epidural catheter removed yesterday.</p>							<p>- 10j PANA 1gm IV 1-0</p> <p>- 10j PAN 40mg IV 1-0</p>
DT-41mmHg	<p>colour - Blood mixed</p> <p>E: Serosanguinous fluid</p>							<p>- 10j CODESET 4mg IV S.O.S</p> <p>- 10j TRAMADOL 2cc</p> <p>in 100ml NS IV S.O.S</p>
								- SYP ASCORIL D 1j
								cough persists 5ml
	To do:							
	- Abdominal Binder Belt (DYNA)							- SYP CREMAMIN PLUS 10ml - 100ml
								- T/PR/BD/SpO2/HR @ 4 th hrly
								- CBD/Drain care



DEAN
SRI MUTHUKUMARAN MEDICAL COLLEGE
HOSPITAL & RESEARCH INSTITUTE
Chikkarayapuram, Near Mangadu
Chennai-600 069

[Signature]
13/11/24



Sri Muthukumar Medical College Hospital and Research Institute
Chikkarayapuram, Near Mangadu, Chennai - 600069

IN-PATIENT PROGRESS RECORD

name	Mu Goutham P	Age	27	Sex	M <input type="checkbox"/> F <input checked="" type="checkbox"/> TG <input type="checkbox"/>	UHID.No	237896
dept	45	Unit	I	Ward	P&W	IP.No	3119
Date & Time	Clinical Notes & Treatment					Investigations	
16/03/24	c/c B DAS Duty P4 / cemi - SV						
6.45pm	- clo chills						
POD-2	Asic → Desmoid tumor of (R) Internal oblique & Transverse Abdominis						
	Slp (R) Desmoid Tumor excision + mesh Repair						
	clo chills					Adv:	
RR-82bpm	ole: gr-fair					- Int AVIL scc, mastat	
Sp-100% sat	febrile					- Stop iv fluids	
SpO2-97.8A						- T. combifcam 1 HC	
RR-16 bpm	S/E. vs - S, S2 ⊕					- Inform SAs	
Temp-99.5°F	RS - R/L NVB ⊕						
	CNS - NEND						
	Pla - soft - B5 ⊕						
	Dressing Intact						
DI in situ	No leakage						
							
<p>DEAN SRI MUTHUKUMARAN MEDICAL COLLEGE HOSPITAL & RESEARCH INSTITUTE Chikkarayapuram Near Mangadu Chennai-600 069</p>							



Sri Muthukumar Medical College Hospital and Research Institute
Chikkarayapuram, Near Mangadu, Chennai - 600069

IN-PATIENT PROGRESS RECORD

Name	Mei Goutham	Age	27	Sex	M <input checked="" type="checkbox"/> F <input type="checkbox"/> TG <input type="checkbox"/>	UHID.No	237047
Dept	CS	Unit	I	Ward	PAW	Bed	IP.No 03119
Date & Time	Clinical Notes & Treatment						Investigations
16/03/2024 8.45am POD3	C/S/BAP/SR/PG/CRMI-SI						
	Δ - ⊕ desmoid tumor Post wide local excision i mesh repair statue						
	No new complaints No c/o fever/chills						Adv-
T-98°F	O/E - Conscious - Soft stool						
PR-76bpm	Oriented						
BP-100/70 mmHg	Afebrile - Plenty of oral fl						
SPO ₂ -98% RA	Hydration fair						
	CNS/RS-NAD						⊕ Dig. Xone 1g 2V/10
DT-10ml (serous)	P/A - Soft, B(+) - T. Ultracet 10-1						
DT was found to be blocked & changed at around 7.00AM	L/E - Wound healthy. C&D done. - T. Pan D 10-1 (R/F)						
Catheter clamped.	- Dig. Tramadol 100mg qn/100ml NS IV SOS						
	- Syp. Cremaphor plus 10ml/10-10ml						
	- Abdominal binder						
	- Vitals monitoring						

[Signature]

DEAN

SRI MUTHUKUMARAN MEDICAL COLLEGE
HOSPITAL & RESEARCH INSTITUTE
Chikkarayapuram Near Mangadu
Chennai-600 069

COL. CHIA (Dr. Sandhya K, M.S)



Sri Muthukumar Medical College Hospital and Research Institute
Chikkarayapuram, Near Mangadu, Chennai - 600069

IN-PATIENT PROGRESS RECORD

name	Mu. Goutham	Age	27	Sex	M <input type="checkbox"/> F <input checked="" type="checkbox"/> TG <input type="checkbox"/>	UHID.No	230476
pt	GS	Unit	I	Ward	PAU	Bed	IP.No 081119
Date & Time	Clinical Notes & Treatment						Investigations
03/24	C/S/B - DAS/AP/Pu/ CRM1 S1						
POD-4	Δ - (R) Desmoid Tumor Sp wide local excision + mesh repair stably						
R - 72bpm	Ab has 1 episode fever spike yesterday evening						
P - 110/80 mmHg	No other complaints						Adu
r - 98.4 f	Pt passed stools						
RR - 16/min	O/F: UC Fair, Afebrile, Adequately hydrated.						- soft diet
	S/F: CVS: S1, S2 @						- Plenty of oral fluids
	RS: B/L NE @						
DT - 4ml	CNS: HMO @						Ds - inj. XONE 1gm IV 1-0-1
- sero sanguineous	P/A: soft, non-tender Two mg. c. analoga, Daudl smudg @						- T. ULTRACET 1-0-1
							- T. PAN-D 1-0-1 (BR)
	L/E: Dressing intact no swabage Drain tube in situ						- inj. TRAMADOL 100mg in 100ml NS IV SOS
							- sup. clemastin plus 10ml 0-10ml
	To do						- Abdominal binder belt
	To collect HPE Report Tomorrow.						
							- T/PR/EP/SW/FE monitor 2h 6h 12h 18h 24h 30h
							- DT. care

[Handwritten Signature]

DEPT
SRI MUTHUKUMAR
MEDICAL COLLEGE
Chikkarayapuram

[Handwritten Signature]
137111



Sri Muthukumar Medical College Hospital and Research Institute
Chikkarayapuram, Near Mangadu, Chennai - 600069

IN-PATIENT PROGRESS RECORD

Name	Mu. Gowthami	Age	47	Sex	M <input type="checkbox"/> F <input checked="" type="checkbox"/>	UHID.No	23704F16
Dept	GS	Unit	J	Ward	POW	IP.No	03119

Date & Time	Clinical Notes & Treatment	
18/03/24	C/S/B - AP/PA/CRMI-S,	
POD-5 8:30 AM	Δ - (A) Dermoid Tumor Post wide local Excision - Mesh Repair Status	
	pt has no complaints	
PR - 80/min	o/e: GC fair, Afebrile, Adequately hydrated	
BP - 110/70 mmHg	S/F: CVS: S, S, D RS: B/LACD NS: HMPD	
SpO ₂ - 97% RA	P/A: Soft, Tenderness (C) surgical site no organomegaly Bowel sounds (C)	
PR - 18/min	- plenty of oral fluids - inj. xone 1gm IV 1-0-1	
	- T. ULTRACET 100	
DT - 10ml (serous)	Wound dressing intact no leakage Drain tube in situ	C & D done. Wound healthy - T. PAN-D 1-0-1 (B/C)
DT removed.	- inj. Tramadol 100mg in 100ml NS IV S/S	
	- sye oemaffin Plus 10ml-0-10ml	
	- Abdominal binder belt	
	- T/PR/BP/spo ₂ /RR etc. daily	

Dr. Sandhya K. M. (MCh)
Dr. M. (MCh)
 13/11/24

To add:
 (D) Inj. Xone 1g IV 1-0-1.



Sri Muthukumar Medical College Hospital and Research Institute
 Chikkarayapuram, Near Mangadu, Chennai - 600069

IN-PATIENT PROGRESS RECORD

Name	Mu. Gowthaman	Age	42	Sex	M <input type="checkbox"/> F <input checked="" type="checkbox"/> TG <input type="checkbox"/>	UHID.No	2370476
Unit	45	Ward	I	Bed	Pou	IP.No	03/119

Date & Time	Clinical Notes & Treatment	Investigations
1/3/24	C/S/B - AP/Pg/CRMS	Rp
12-6	Δ - (R) Desmoid Tumor	- soft diet
7.30am	S/P - Post wide Local Excision	- plenty of oral fluids
	Mesh Repair status.	- T. UCTRACET (60.5)
	pt has no new specific complaints.	T. PAN-D 1-0-(CRF) x5days
- Sp/min		Sp. CEFHAFFIN PLUS 10ml-0-10ml
- 120/80mmHg		Abdominal binder belt
	O/E: GC - Conscious, Oriented, afebrile.	- TPR/BP changing
	S/E: CVS - S1S2 ⊕	No add
	RS - B/C ⊕	1- CEFARIND 500mg 1-0-10 x5days
	CNS - NFND	
	P/A - soft, BS ⊕	
	L/E: Dressing intact no leakage	
	plan: Discharge today.	

Dr. Priffy 159355

[Handwritten Signature]

DEAN
SRI MUTHUKUMARAN MEDICAL COLLEGE
HOSPITAL & RESEARCH INSTITUTE
 Chikkarayapuram Near Mangadu
 Chennai-600 069



Sri Muthukumar Medical College Hospital and Research Institute
Chikkarayapuram, Near Mangadu, Chennai - 600069

OPERATION NOTES

PATIENT NAME	Mrs. hewtham	AGE/SEX	27 / F	UHID. NO	2370476
DEPT/UNIT	h3-1	WARD/BED	205	IP. NO	31119

DATE: 13/03/2024. TIME:


PRE OPERATIVE DIAGNOSIS	(A) internal oblique desmoid tumour.
POST OPERATIVE DIAGNOSIS	(R) internal oblique & transverse abdominal desmoid tumour.
OPERATION PROCEDURE	Excision of desmoid tumour (R) & mesh repair.
SURGEON: Dr. P. Sri Dr. Kaishna Kumar M.Ch Dr. Rithan, M.S Dr. Sandhya K. M.S	TYPE OF ANAESTHESIA: GA & Epidural. ANAESTHETIST: Dr. Kavin M.D. Dr. Yuvasee M.D.
ASST. SURGEON: 1. Dr. Abraham PG-I 2. 3.	SCRUB NURSE: S/N Yamuna. FLOOR NURSE: OT TECHNICIAN:
INCISION	Elliptical incision around previous incisional biopsy scar.

DEAN
SRI MUTHUKUMARAN MEDICAL COLLEGE
HOSPITAL & RESEARCH INSTITUTE
Chikkarayapuram, Near Mangadu
Chennai-600069

Name
Dept
Date &

FINDINGS	4 x 3 cm tumour arising from internal oblique & transverse abdominis; adhesion to underlying transversalis fascia & peritoneum
PROCEDURE	Above incision made & excised intracorporeally. The ext. oblique aponeurosis opened. tumour identified & excised in toto giving 2cm clearance on all sides. Peritoneum was opened and no excision was found intraperitoneally and underlying peritoneum also excised. Peritoneum closed using 2-0 vicryl mesh placed and fixed to fascia transversalis medially, superiorly remains int. oblique and lateral inter. oblique aponeurosis and inferior subpubic part. Ag-S of terminal ileum overlies mesh approximated & closed. Another mesh fixed over the F.O.A. wound closed in layers.
DRAINS	
CLOSURE	
SUTURE MATERIAL USED:	
INSTRUMENT COUNT (CORRECT):	
PAD / GAUZE COUNT (CORRECT):	
BLOOD TRANSFUSION:	
BLOOD LOSS:	
I.V. FLUIDS:	
SAMPLE FOR HPE	sent for HPE.

DEPARTMENT OF SURGERY

CONSULTANT
(NAME & SIGN)  DR. SANDHYA.K, M.S.

H.O.D
(NAME & SIGN)

DATE: 13/3/2024.


DEAN
SRI MUTHUKUMARAN MEDICAL COLLEGE
HOSPITAL & RESEARCH INSTITUTE
Chikkarayapuram Near Mangadu
Chennai-600 069



Sri Muthu

PATIENT NAME: MM.
DEPT/UNIT: (

PROCEDURE STARTING:
PROCEDURE ENDING:
SPECIMEN: Per
SAMPLE SENDING:
Patient condition & Vitals:

Packing
Implant/ pr
Ryles tub
Urinary c
Drains
Stoma

Pr
A



**SRI MUTHUKUMARAN
MEDICAL COLLEGE HOSPITAL AND RESEARCH INSTITUTE**

Chikkarayapuram, Near Mangadu, Chennai - 600 069.

03 FEB 2024

OUTPATIENT RECORD

G.S.M

UHID. No. : 2374764
Name : Mr. Sakthi
Age & Sex : 27 / m
Address : 510 Iyyar Ppam

21, Indira Amella St
Old Pallarasam

Contact No. :


DEAN
SRI MUTHUKUMARAN MEDICAL COLLEGE
HOSPITAL & RESEARCH INSTITUTE
Chikkarayapuram Near Mangadu
Chennai-600 069

அடுத்த முறை வரும் பொழுது இந்த அட்டையை
தவறாமல் கொண்டுவரவும்

45601

Height :

Weight :

BMI :

Temp :

PR :

BP :

Pain Score :

Allergy :

SPO₂ :

CBG :

RR :

Complaints :

10/02/2024

GIS/B GIS IV AP / PG / CRMI

- Pt. 90 swelling in the anal region
a/w pain

- No H/O passing blood in stools
- No H/O constipation

History of Present illness :

Past illness / Any previous surgery :

Pt. has no known co-morbidities

DEAN
 SRI MUTHUKUMARAN MEDICAL COLLEGE
 HOSPITAL & RESEARCH INSTITUTE
 Chikkarayapuram Near Mangadu
 Chennai-600 069

Personal History : Smoking Alcohol Tobacco

Others : _____

Immunization Status : COVID-19 / Hepatitis B / Others

Clinical Examination :

O/E;

Grc fair; afebrile

S/E

CVG: 5, 5, 2 ⊕

RS: NV05 ⊕

P/A: Spk

CNG: NFND

Local Examination :

L/E

P/L:

Non-bleed stained

spoon ⊕

? Enteral hemorroids at

3rd clear position

Investigations :

Date	Tests	Reports

DEAN
SRI MUTHUKUMARAY MEDICAL COLLEGE
HOSPITAL & RESEARCH INSTITUTE
Chikkarayapuram, Srirangapatna
Chennai-600 059

Provisional / Final Diagnosis :

? External Hemorrhoids

Treatment Plan : (Curative / Preventive / Palliative / Rehabilitative)

Advice
High fibre diet

Diet Advice :

Followup Advice :

Review Date :

Doctor's Name :

Signature :

Reg. No. :

Date :

OUT PATIENT PRESCRIPTION

புற நோயாளிகள் மருந்து கட்டு

S.NO.	DRUG NAME மருந்துகள்	DOSE அளவு	ROUTE மாதிரி	MORNING BF/AF புறநாள்/ உள்ளாள்/ உணர்	A.NOON BF/AF புறநாள்/ உள்ளாள்/ உணர்	EVENING BF/AF புறநாள்/ உள்ளாள்/ உணர்	NIGHT BF/AF புறநாள்/ உள்ளாள்/ உணர்	DURATION கால அளவு
1.	DISPO GLOVES - 2 PAIRS							
2.	BETADINE SOLUTION - ①			1	-	-	1	5 DAYS
3.	CEPHRADIN CT			1	-	-	1	
4.	T. OMEEZ			✓	-	-	✓	
5.	ANDWAIT OINTMENT 1/A							

DEAN
SRI MUTHUKUMARAI MEDICAL COLLEGE
HOSPITAL & RESEARCH INSTITUTE
Sri Muthukumarai Medical College
Sri Muthukumarai Medical College
Sri Muthukumarai Medical College

CONFIDENTIAL

NOT TO BE HANDLED BY THE PATIENT

Handwritten signature and date: 10/24

SURGERY OPD

29/8/2011

- patient came for review
- also see patient - see

From,
Senior Resident
Department of General Surgery
Srinagar

To,
The Assistant Professor
Department of Anesthesiology
Srinagar

Respected Sir, Madam,
Kindly assess the patient Mr. Sankar, 27 yrs old, with diagnosis of Fistula In Ano, posted for fistulotomy
Thanking you
Srinagar

(Srinagar)

48-2

~~08/09/2011~~ also see patient - see

- patient came for review
- Case of Fistula - In - Ano

Plt: External opening at 12 o'clock
Active pus discharge
Induration
Internal opening at 12 o'clock position

(Srinagar)

DEAN
SRINIVASAN MEDICAL COLLEGE
HOSPITAL & RESEARCH INSTITUTE
Chikkavayaluram, Near Mangadu
Chennai-600 069

8/5/24

SURGERY OPD

o/s/g PEP p/q/cems - SLD

- Patient come for Review

P/R → External opening at 1'o
clock position

Internal opening at 12'o
clock position

Intersphincteric Tone - (N)

Imp - Fistula In Ano

Adv

Plan for fistulotomy

Amtho
in Ano (cm)



DEAN
SRI MUTHUKUMARAN MEDICAL COLLEGE
HOSPITAL & RESEARCH INSTITUTE
Chikkarayapuram, Near Mangadu
Chennai-600 059

OUT PATIENT PRESCRIPTION
புற நோயாளிகள் மருந்து சீட்டு

S.NO.	DRUG NAME மருந்துகள்	DOSE அளவு	ROUTE வழி	MORNING BF/AF காலை உழுள்/ உபிள்	A.NOON BF/AF மதியம் உழுள்/ உபிள்	EVENING BF/AF மாலை உழுள்/ உபிள்	NIGHT BF/AF இரவு உழுள்/ உபிள்	DURATION கால அளவு
①	TAB. GUDCEF CV	625mg			—————			⑩
②	TAB. FLAGYL	400mg						⑮
③	TAB. PAN	40mg	B/F		—————			⑦
④	SITZ BATH	BID						
⑤								


SRI MUTHUKUMARAN MEDICAL COLLEGE
HOSPITAL & RESEARCH INSTITUTE
 Chikkalapuram, Near Mangaluru
 Chennai-600 069

Provisional / Final Diagnosis :

? External hemorrhoids

Treatment Plan : (Curative / Preventive / Palliative / Rehabilitative)

Advice
High fibre diet

Diet Advice :

Followup Advice :

Review Date :

Doctor's Name :
Signature :
Reg. No. :
Date :

OUT PATIENT PRESCRIPTION

புற நோயாளிகள் மருத்து சீட்டு

S.NO	DRUG NAME மருந்தின் பெயர்	DOSE அளவு	ROUTE வழி	MORNING BF/AF முற்பகல் / ப. பின்பகல்	A.NOON BF/AF முற்பகல் / ப. பின்பகல்	EVENING BF/AF முற்பகல் / ப. பின்பகல்	NIGHT BF/AF முற்பகல் / ப. பின்பகல்	DURATION கால அளவு
1.	DISPO GLOVES - 2 PAIRS							
2.	BETADINE SOLUTION - ①							
3.	CEPHRAOX CT			1	-	-	1	5 DAYS
4.	T. OMEEZ			1	-	-	1	
5.	ANOWAIT OINTMENT 1/A			✓	-	-	✓	

10/24

DEAN
SRI MUTHUKUMARAN MEDICAL COLLEGE
HOSPITAL & RESEARCH INSTITUTE
Chikkarayapuram - Near Mangadu
Chennai-600 069

Handwritten notes and date: 10/24

CONFIDENTIAL
NOT TO BE HANDLED BY THE PATIENT

OUT PATIENT PRESCRIPTION

೧೦) ಭಕ್ತುರಾಜ್‌ನಿಗೆ ೧೦ ದಿನಕ್ಕೆ ಸಿ. ೬

S.NO.	DRUG NAME ಉಪಯೋಗ	DOSE ಮಾಪ	ROUTE ಕಾಜಿ	MORNING	A NOON	EVENING	NIGHT	DURATION ಮಾಪ ದಿನ
				AM / PM ಉಪಯೋಗ ಒಮ್ಮೆ / ಒಮ್ಮೆ	AM / PM ಉಪಯೋಗ ಒಮ್ಮೆ / ಒಮ್ಮೆ	AM / PM ಉಪಯೋಗ ಒಮ್ಮೆ / ಒಮ್ಮೆ	AM / PM ಉಪಯೋಗ ಒಮ್ಮೆ / ಒಮ್ಮೆ	
	Dispozolam		(S) pain					
1.	T. Parimol	200mg		1	---		1	(1)
2.	T. Parimol Neurogyl	400mg		1	---		1	(6)
3.	C. omox D (s/r)			1	---		1	(6)
4.	Syr. Diphthalac	10ml			---		1	
	Sitng bath Bd.					2		

Bill No. 0262907
447



DEAN
SRI MUTHUKUMARAH MEDICAL COLLEGE
HOSPITAL & RESEARCH INSTITUTE
Chikkarayapuram Near Mangadu
Chennai-600 069

SURGERY OFFICE